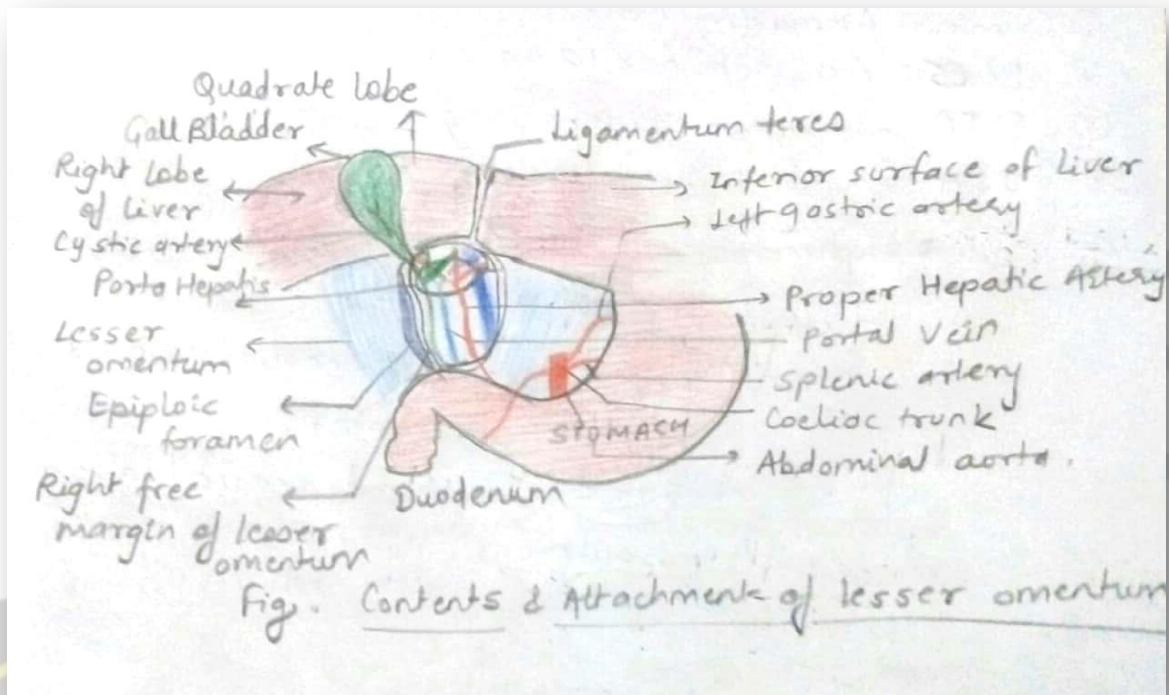


LESSER OMENTUM

Hello everyone today we will be learning about lesser omentum.

- ❖ Lesser omentum is the double layer of peritoneum that extends from the **liver to the lesser curvature of the stomach and the first part of the duodenum**. It has a right free margin behind which there is epiploic foramen.
- ❖ Epiploic foramen or foramen of Winslow serves as passage between greater and lesser sacs.
- ❖ Lesser omentum is subdivided into:
 - a) **Hepatogastric ligament**-extending from liver to lesser curvature of stomach(the name itself suggests)
 - b) **Hepatoduodenal ligament**-extending from liver to first part of duodenum (same here as well)
- ❖ **Attachments**
 - Inferiorly to the lesser curvature of stomach and first part of duodenum
 - Superiorly to liver in the form of inverted L.



❖ Contents

Now this is going to be a treat for HP fans :)

1) Right free margin contains

Mnemonic-Harry Potter Loves Drinking Butterbeer with Hermione and Neville

Harry-	Proper Hepatic artery
Potter-	Portal vein
Loves-	Lymph node and lymphatics
Drinking butterbeer-	Bile duct
With Hermione and Neville-	Hepatic plexus of Nerves

2) Along lesser curvature of stomach and along upper border of adjoining part of duodenum it contains

Mnemonic- 4G (nerves, vessels, lymphatics related to gaster)

- 1) Right **G**astric vessels
- 2) Left **G**astric vessels
- 3) **G**astric group of lymph node and lymphatics
- 4) Branches from **G**astric nerves

And that's all :)

-Anuja Mandavkar

